

ISSN Print: 2520-5552

ACE Journal of Neurosciences
https://acejneuro.com/

Research Article

Clinico-Genetic Profile of GNE Myopathy: A Case from Central India

Nidhita[1*], Dinesh Kumar Udainiya[2], Arvind Gupta[3] and Saurabh Singh Rajput[4]

[1]DM Resident, Department of Neurology, J A Group of Hospitals and GRMC, Gwalior, Madhya Pradesh, India
[2]Professor and HoD, Department of Neurology, J A Group of Hospitals and GRMC, Gwalior, Madhya Pradesh, India
[3]Associate Professor, J A Group of Hospitals and GRMC, Gwalior, Madhya Pradesh, India
[4]Assistant Professor, J A Group of Hospitals and GRMC, Gwalior, Madhya Pradesh, India

***Corresponding Author**
Dr. Nidhita
(nidhitarockin@gmail.com)

Article History
Received: 01.10.2026
Accepted: 24.10.2026
Published: 07.11.2026

DOI: 10.61336/acejn.0404.05

Abstract: Background: GNE myopathy is a rare autosomal recessive distal myopathy caused by biallelic variants in GNE, the gene encoding a bifunctional enzyme involved in sialic acid biosynthesis. It characteristically presents with progressive distal lower-limb weakness and relative preservation of quadriceps strength. **Case Presentation:** A 40-year-old man presented with a four-year history of progressive lower-limb weakness, initially more pronounced on the left, followed by distal upper-limb weakness and muscle wasting. Examination showed severe bilateral ankle weakness (Medical Research Council grade 1/5), wrist weakness (3/5) and relative preservation of knee extension, without sensory loss. Serum creatine kinase was normal (72 U/L). Nerve conduction studies were reported as showing lower-limb motor axonal neuropathy, while needle electromyography showed mixed findings. Whole-exome sequencing identified two heterozygous GNE variants (transcript NM_005476.7): c.2086G>A (p.Val696Met), classified as pathogenic in the laboratory summary table and c.1538G>A (p.Trp513Ter), classified as likely pathogenic. The laboratory interpreted the combination as likely compound heterozygous; phase was not confirmed. **Conclusion:** The clinical pattern of progressive distal weakness with relative quadriceps sparing can indicate GNE myopathy despite normal creatine kinase and potentially misleading electrophysiological results. This case illustrates the contribution of molecular testing, while also highlighting the need to establish the cis/trans phase of two detected heterozygous variants before claiming confirmed biallelic disease.

Keywords: Myopathy, Genetics, Neuromuscular, Distal Myopathy, Foot Drop, Case Report

Copyright @ 2026: This is an open-access article distributed under the terms of the Creative Commons Attribution license which permits unrestricted use, distribution and reproduction in any medium for non-commercial use (NonCommercial, or CC-BY-NC) provided the original author and source are credited.

INTRODUCTION

GNE myopathy, previously described as Nonaka myopathy, distal myopathy with rimmed vacuoles, hereditary inclusion body myopathy, or quadriceps-sparing myopathy, is a rare, slowly progressive, autosomal recessive skeletal-muscle disorder. It results from biallelic pathogenic variants in GNE, which encodes the bifunctional UDP-N-acetylglucosamine 2-epimerase/N-acetylmannosamine kinase enzyme required for sialic acid biosynthesis [1,2]. The condition typically emerges in early adulthood with weakness of ankle dorsiflexion and foot drop, followed by involvement of other lower-limb and subsequently upper-limb muscle groups; knee extensors are often relatively preserved [1,2]. Serum Creatine Kinase (CK) may be normal or mildly elevated and molecular testing provides diagnostic confirmation when pathogenic variants are established in trans [1].

Indian cohorts have identified recurrent GNE variants and a broad clinical spectrum, including variable age at onset and rates of progression [3,4]. We describe a patient from Central India with progressive distal weakness, quadriceps sparing and two reported GNE sequence variants, highlighting the diagnostic value of phenotype-guided genetic evaluation.

Case Presentation

Patient Information and Clinical History

A 40-year-old man, with no history of diabetes or hypertension and born to non-consanguineous parents, attended the neurology outpatient department with gradually progressive limb weakness of four years' duration. He initially experienced difficulty lifting one leg while standing on the other to put on trousers. Symptoms were more severe on the left but involved both lower limbs within six months. During the subsequent two years, he developed distal upper-limb weakness. Over the preceding year, he noticed progressive wasting of the distal legs, later involving the distal forearms.

He denied episodes of knee buckling, neck or truncal weakness, myalgia, dark-coloured urine, sensory symptoms, cranial nerve complaints, sphincter dysfunction, seizures, headaches, or loss of consciousness. There was no known family history of a similar illness.

Clinical Examination

He was thin-built with stable vital signs. Cranial nerve examination was unremarkable. Generalised reduction in muscle bulk was noted, more evident distally, with normal tone and no abnormal involuntary movements. Neck flexion and extension were preserved and there was no scapular winging. Wrist flexion and extension were Medical Research Council (MRC) grade 3/5, with reduced handgrip strength. Bilateral ankle dorsiflexion and plantarflexion were MRC grade 1/5. Knee flexion was weak, whereas knee extension was relatively preserved. Mild weakness was also described in hip flexion, extension, abduction and adduction, although numerical MRC grades were not documented. Deep tendon reflexes and sensory examination were normal and no cerebellar signs were elicited (Table 1).

Diagnostic Assessment

Serum CK was normal at 72 U/L. Selected results were: aspartate aminotransferase 72 U/L, alanine aminotransferase 142.9 U/L, erythrocyte sedimentation rate 46 mm/h, creatinine 0.55 mg/dL, sodium 140 mmol/L and potassium 3.8 mmol/L. Ultrasound demonstrated fatty liver. HIV, hepatitis B surface antigen and hepatitis C testing were negative. Echocardiography showed a left ventricular ejection fraction of 60% without a documented structural abnormality. The complete biochemical findings in the source manuscript should be checked against laboratory units and reference intervals before publication.

Nerve conduction studies were interpreted in the original record as suggestive of axonal motor neuropathy in both lower limbs. Needle electromyography of the right tibialis anterior showed positive sharp waves and small-amplitude polyphasic motor unit potentials with no recorded interference pattern. The right vastus lateralis showed occasional endplate spikes with a normal interference pattern. No interference pattern was recorded from the right extensor digitorum brevis. High-amplitude motor unit potentials were described in the bicep's muscles. Thus, the electrophysiological findings were heterogeneous rather than uniformly myopathic; raw nerve conduction and EMG data would help clarify this discrepancy.

Bilateral thigh MRI demonstrated T2/STIR hyperintensity in posterior-compartment musculature and adjacent tissues, interpreted in the source record as possible oedematous change. Muscle-specific involvement and fatty infiltration could not be reliably determined from the supplied description.

Whole-exome sequencing on peripheral-blood DNA identified two heterozygous GNE variants, both annotated against NM_005476.7. Variant 1, c.2086G>A (p.Val696Met), was a missense change in exon 12, listed as pathogenic in the laboratory classification table (ACMG evidence codes PM1, PP2, PP3, PS1). Variant 2, c.1538G>A (p.Trp513Ter), was a stop-gain (nonsense) change in exon 9, listed as likely pathogenic (PM2, PVS1). The laboratory described these as likely compound heterozygous variants related to the phenotype (Table 2).

Diagnostic Considerations

The phenotype of progressive distal-predominant weakness with relative knee-extensor sparing strongly suggested GNE myopathy. Other diagnostic possibilities at presentation included hereditary motor neuropathy, other distal myopathies and selected myofibrillar or vacuolar myopathies. Preservation of sensation, the pattern of muscle involvement and the reported GNE findings favoured a primary hereditary myopathy, while the nerve conduction interpretation requires clinical correlation.

Treatment, Follow-up and Patient Perspective

Details of rehabilitation, assistive devices, genetic counselling, follow-up interval, functional outcome and the patient's perspective were not recorded in the supplied manuscript and should be added if available. No treatment or outcome has been assumed in this revision (Figures 1-3).

Table 1: Timeline

Time relative to presentation	Reported clinical course
Four years earlier	Lower-limb weakness began; initially left greater than right
Within six months of onset	Weakness became bilateral
Two years before presentation	Distal upper-limb weakness developed
One year before presentation	Visible distal leg wasting, followed by distal forearm wasting
At presentation	Marked bilateral ankle weakness, relative quadriceps sparing, laboratory and neurophysiological evaluation

Table 2: Whole-Exome Sequencing Results Showing two Likely Compound Heterozygous GNE Variants, their Molecular Effects, Exon Locations and Pathogenicity Classifications

Variant (NM_005476.7)	Exon	Zygosity	Molecular effect	Lab classification
c.2086G>A (p.Val696Met)	12	Heterozygous	Missense	Pathogenic
c.1538G>A (p.Trp513Ter)	9	Heterozygous	Stop-gain	Likely pathogenic



Figure 1: Lower Limbs



Figure 2: Forearm/Hand

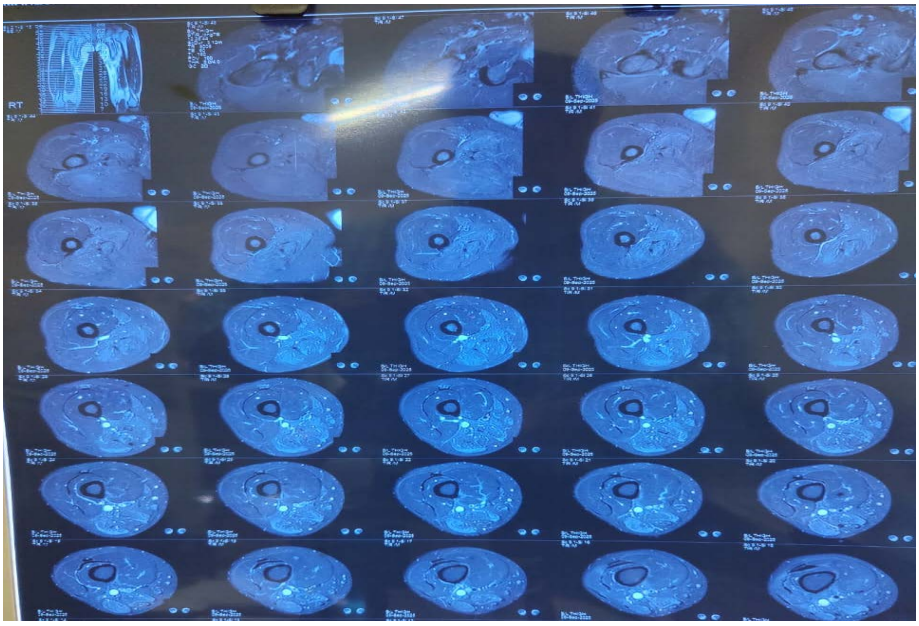

Figure 3: Thigh MRI

DISCUSSION

GNE myopathy is an uncommon cause of adult-onset distal-predominant weakness. In its classical form, weakness begins with the tibialis anterior and other lower-leg muscles, often producing foot drop, then progressively affects hamstrings, proximal lower limbs and upper limbs. Relative preservation of quadriceps strength remains a diagnostically useful clue, although it is not absolute and may diminish with disease progression [1,2,5]. In our patient, severely reduced ankle strength, distal muscle wasting and relative preservation of knee extension closely fit this recognisable pattern.

Clinical heterogeneity is important. An Indian cohort study of 157 patients described foot drop as the most common presenting symptom and found that compound heterozygous variants were frequent; a subset had early proximal or quadriceps involvement [4]. The reported clinical features in this case therefore support GNE myopathy without being individually pathognomonic. The absence of a family history does not exclude autosomal recessive disease, particularly in non-consanguineous families [1].

Normal CK does not rule out GNE myopathy. CK concentrations are frequently normal or only modestly elevated and muscle biopsy, when performed, may show rimmed vacuoles without inflammation [1,2,5]. The posterior-thigh MRI abnormalities reported here are broadly compatible with muscle involvement but are insufficiently detailed to establish a characteristic distribution. The normal quadriceps function and reduced hamstring power may be more informative than an isolated nonspecific STIR signal change. Quantitative MRI or muscle-by-muscle reporting could strengthen the radiological correlation.

The reported motor-axonal nerve conduction interpretation and high-amplitude motor units in some sampled muscles deserve particular attention. GNE myopathy can show variable or nonspecific electrophysiological findings; nonetheless, electrophysiological evidence suggesting neurogenic involvement should not be silently recast as purely myopathic [2]. Repeat testing or review of raw waveforms, recruitment patterns and sensory responses could help distinguish concomitant neuropathy, sampling limitations and muscle disease-related changes.

The genetic findings in this patient merit precise interpretation. The laboratory identified heterozygous GNE c.2086G>A (p.Val696Met), a missense variant in exon 12 and heterozygous c.1538G>A (p.Trp513Ter), a stop-gain variant in exon 9, using transcript NM_005476.7. The p.Val696Met variant was designated pathogenic in the report summary; the p.Trp513Ter variant was designated likely pathogenic. Importantly, Nalini and colleagues previously reported c.2086G>A (p.Val696Met) in six of eight Indian families studied, supporting the regional relevance of the detected missense variant [6].The laboratory described p.Trp513Ter as absent from the population databases it queried; this statement is restricted to the reporting date and should not be taken as proof of worldwide novelty. Premature stop codons can result in truncated proteins or nonsense-mediated mRNA decay, but no functional assessment was performed for this individual [1,5]. As GNE myopathy is autosomal recessive, the two heterozygous variants require confirmation of their trans configuration to establish a definitive biallelic molecular diagnosis. In the absence of reported parental segregation testing or Sanger confirmation, they are best described as likely compound heterozygous [1].

GNE myopathy generally progresses slowly and supportive care includes multidisciplinary rehabilitation, mobility aids, fall prevention and genetic counselling [1,6,7]. Cardiac involvement is not usually a prominent feature and clinically significant respiratory involvement is uncommon, although clinical assessment may be appropriate in advanced disease [1,2,7]. This case illustrates a clinically recognisable phenotype from Central India; limitations include unconfirmed variant phase, no documented muscle biopsy and absence of longitudinal follow-up or patient-reported outcomes.

CONCLUSION

This case highlights GNE myopathy as an important consideration in adults presenting with slowly progressive distal-predominant limb weakness and relative quadriceps sparing, even with normal creatine kinase or electrophysiological findings suggestive of motor neuropathy. Whole-exome sequencing identified a reported pathogenic missense GNE variant, p.Val696Met and a likely pathogenic stop-gain variant, p.Trp513Ter, both in the heterozygous state. Although this combination strongly supports the clinical suspicion of GNE-related myopathy, the variants remain likely compound heterozygous until their trans configuration is established. Genetic counselling, confirmatory testing and segregation analysis are therefore important for accurate molecular diagnosis and family risk assessment.

REFERENCES

1. Carrillo, N. *et al.* GNE myopathy. In: GeneReviews® [Internet]. Seattle (WA): University of Washington, Seattle; 1993-2026. Updated April 9, 2020. https://www.ncbi.nlm.nih.gov/books/NBK1262/.
2. Carrillo, N. *et al.* "GNE myopathy: Etiology, diagnosis and therapeutic challenges." *Neurotherapeutics*, vol. 15, pp. 900-914, 2018. DOI:10.1007/s13311-018-0671-y.
3. Chakravorty, S. *et al.* "Clinical and genomic evaluation of 207 genetic myopathies in the Indian subcontinent." *Frontiers in Neurology*, vol. 11, 559327, 2020. DOI:10.3389/fneur.2020.559327.

4. Baskar, D. *et al.* "GNE myopathy: Genotype-phenotype correlation and disease progression in an Indian cohort." *Journal of Neuromuscular Diseases*, vol. 11, no. 5, pp. 959-968, 2024. DOI:10.3233/JND-230130.
5. Pogoryelova, O. *et al.* "GNE myopathy: From clinics and genetics to pathology and research strategies." *Orphanet Journal of Rare Diseases*, vol. 13, 70, 2018. DOI:10.1186/s13023-018-0802-x.
6. Nalini, A. *et al.* "GNE myopathy in India." *Neurology India*, vol. 61, no. 4, pp. 371-374, 2013. DOI:10.4103/0028-3886.117609.
7. Nishino, I. *et al.* "GNE myopathy: current update and future therapy." *Journal of Neurology, Neurosurgery and Psychiatry*, vol. 86, pp. 385-392, 2015. DOI:10.1136/jnnp-2013-307051.